

Metastasis of Serous Ovarian Carcinoma to the Breast: A Case Presentation

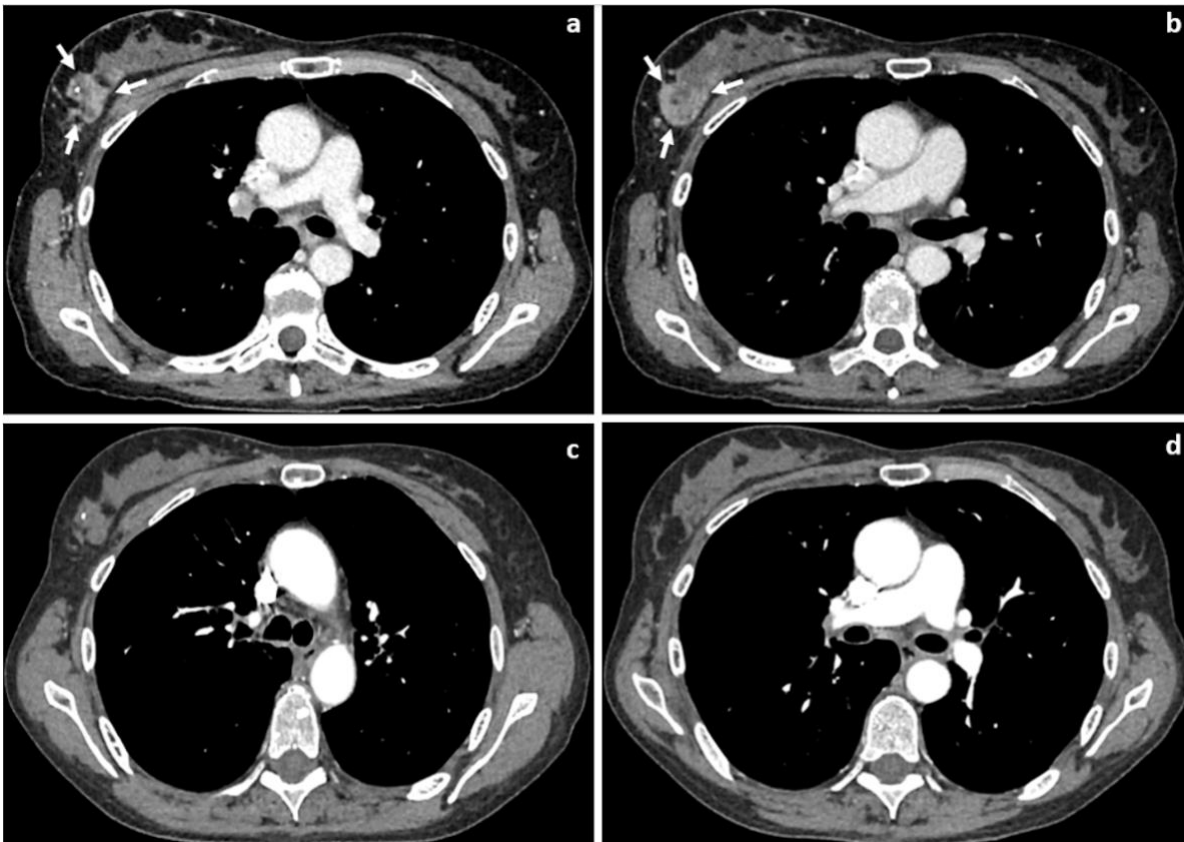
Authors: Sofia Dueño M.D., Rachel Stein D.O., Karina Hew M.D.

Background: Ovarian cancer is the fifth leading cause of cancer deaths in women in the United States. It is characterized by intraperitoneal dissemination in about 85% of cases and distant metastasis is less frequent. Breast metastasis from primary ovarian cancer is rare, with an estimated frequency of 0.07%. More than 110 cases are reported in the literature of metastatic spread of ovarian cancer to the breast and axilla. This entity usually represents aggressive late disease characterized by multi-drug chemoresistance and a poor prognosis with a median survival time of 16 months.

Objective: To present a case of breast metastasis from high-grade serous ovarian cancer and provide a brief review of current literature that details modes of treatment and survival time after diagnosis of breast metastasis.

Case Presentation: A 59-year-old (gravid 0) BRCA-negative Caucasian woman presents with recurrent platinum resistant high-grade serous adenocarcinoma of the ovary. She initially underwent neoadjuvant platinum-based chemotherapy followed by optimal interval debulking. During her fourth line of chemotherapy, she presented with a palpable, firm, and irregular 5.5 cm breast mass in the right upper-outer quadrant with nipple retraction. Right axillary lymphadenopathy was also seen on interval CT imaging and confirmed on a diagnostic mammogram. She had ultrasound-guided biopsies of the breast mass and axillary lymph nodes, which confirmed metastatic high-grade serous adenocarcinoma of ovarian origin. She underwent palliative radiation to the right breast using the Baillet regimen. A total dose of 2300cGy was delivered in 4 fractions, 500cGy on days 1 and 3 and 650cGy on days 15 and 17. Once completed, this was followed by a 5th line of chemotherapy. She had a good clinical response to treatment, as noted on physical exam and 12-week post-treatment imaging. After 8 months, she presented with a local recurrence of the breast mass in the radiated field and worsening lymphadenopathy. She is currently on a 6th line of chemotherapy.

Images



Axial CT chest with intravenous contrast. Pre-treatment CT chest (**a-b**) demonstrates a heterogeneous enhancing mass (white arrows) in the right upper outer breast. Biopsy clip is noted. Post-treatment CT chest (**c-d**) demonstrates no enhancement and decreased size of the right upper outer breast mass, particularly the more inferior portion (**d**).

Discussion: The incidence of breast metastasis from ovarian cancer is about 0.07%, with over 110 cases described in the literature. Treatment options include palliative radiation, mastectomy, lumpectomy, and systemic chemotherapy. Systemic chemotherapy is reported as the initial mode of treatment, with radiation and surgery considered secondary options. There is no consensus on the optimal treatment modality. The literature suggests that the presence of breast metastasis portends a poor prognosis with a mean survival of 16 months. A retrospective cohort of 169 patients from a single university cancer center in the United States with pathology confirmed metastasis to the breast from extramammary primary solid organ tumors revealed a 10-month median duration of survival from the time of breast metastasis diagnosis. In a case series over a 14-year period (1990-2003) at a university cancer center in the United States of 18 patients with ovarian or peritoneal serous ovarian carcinoma with metastasis to the breast and/or axillary lymph nodes, seven patients died of disease after an averaged 12-month follow-up period. Our patient remains alive on active chemotherapy treatment and is now 15 months since her initial diagnosis of breast metastasis.

Conclusion: Metastatic spread of ovarian cancer to the breast is associated with chemotherapy-resistant ovarian cancers and is also associated with poorer outcomes amongst ovarian cancer patients. Breast metastasis from ovarian cancer impacts the quality of life, and more data is needed to determine how to optimally these patients.