

# Complete Uterine Septum: Surgical Resection Challenges in a Patient with Infertility

Grace Thayer, BS; Mariam Barseghyan, MD, MS; Leah Ginn DO, MS; Larisa Gavrilova-Jordan, MD<sup>1</sup>

<sup>1</sup>Department of Obstetrics and Gynecology, Division of Reproductive Endocrinology, Infertility and Genetics, Medical College of Georgia at Augusta University

 **SAAOG**  
Annual Meeting • 2026  
JANUARY 24 - 26, 2026

## Background

A uterine septum is the most common Mullerian anomaly, resulting from post-fusion recanalization failure of the mullerian ducts. It poses reproductive risks including recurrent pregnancy loss, subfertility, preterm labor, and malpresentation. Hysteroscopic resection can improve reproductive outcomes<sup>1</sup>. This case involves a 32 year old G1P0010 female undergoing a staged hysteroscopic resection of a complete uterine septum.

## Case Introduction

32 year old G1P0010 female with 6 year history of secondary infertility and prior spontaneous abortion at 14 weeks, managed surgically. Saline Infusion Sonogram suggested a mullerian anomaly and Pelvic MRI confirmed complete uterine septum to the level of the cervical os. The patient had no renal or other malformations.

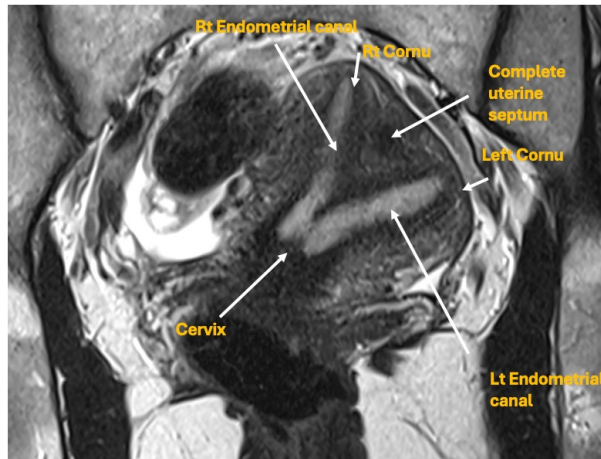


Figure 1. Pelvic magnetic resonance imaging (MRI), T2 weighted coronal view.

## Surgical Management

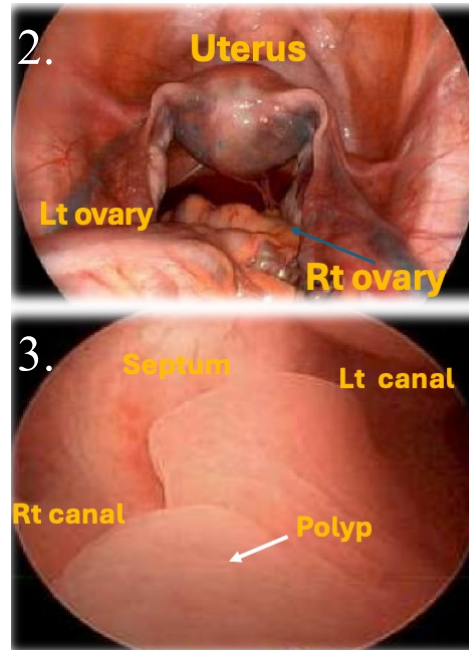


Figure 2: Laparoscopic view with bilateral tubal spill of methylene blue Figure 3 Hysteroscopic view showing polyps in lower uterine segment

### Hysteroscopic resection Stage 1:

- Cervical laxity prevented adequate distention of uterine cavity distension; some improvement after adding a 2nd tenaculum and ring forceps
- After successful resection of 2 cm of uterine septum, procedure aborted due to insufficient cervical seal causing limited visualization

### Interval Management

- 2-month recovery interval

### Hysteroscopic resection Stage 2:

- Hysteroscope compatible with Symphion™ Tissue Removal System
- Improved cervical seal allowed consistent visualization
- Residual septum resected under hysteroscopic and laparoscopic transillumination to ensure no perforation

### Post-operative management

- Intrauterine balloon × 5 days with Doxycycline prophylaxis
- Estradiol patch 0.1 mg twice weekly × 3 weeks
- Progesterone 200 mg PO daily to induce withdrawal bleed after completion of estradiol
- SIS at 3 month follow-up

## CONCLUSION

- Complete septum resection may improve reproductive outcomes in women with a history of miscarriage and infertility
- ASRM 2024 Guidelines: insufficient evidence that resection increases live birth rate, therefore shared decision-making is recommended<sup>2</sup>
- Complete septum resection may be offered for recurrent miscarriage and could reduce adverse obstetric outcomes (e.g., malpresentation, cesarean). High-quality data are limited<sup>2</sup>
- Strategic surgical planning (staged approach and adjuncts) improves safety and outcomes

## References

1. Noventa M, Spagnol G, Marchetti M, Saccardi C, Bonaldo G, Laganà AS, et al. Uterine Septum with or without Hysteroscopic Metroplasty: Impact on Fertility and Obstetrical Outcomes-A Systematic Review and Meta-Analysis of Observational Research. J Clin Med. 2022 Jun 8;11(12):3290.
2. Evidence-based diagnosis and treatment for uterine septum: a guideline. Fertility and Sterility, Volume 122, Issue 2, 251 - 265